



Simple technique to treat pupillary capture after transscleral fixation of intraocular lens

Ignasi Jürgens, MD, PhD, Amanda Rey, MD, PhD

We describe a simple surgical technique to manage pupillary capture after previous transscleral fixation of an intraocular lens.

Financial Disclosure: Neither author has a financial or proprietary interest in any material or method mentioned.

J Cataract Refract Surg 2015; 41:14–17 © 2015 ASCRS and ESCRS

 Online Video

Intraocular lens (IOL) dislocation is an uncommon but potentially serious complication of modern cataract surgery.¹ Zonule or capsule rupture during cataract surgery is thought to be the major cause of early dislocation of an IOL, whereas trauma and pseudoexfoliation have been reported as the main causes of spontaneous late-onset dislocation of the IOL–capsular bag complex.²

A dislocated IOL often requires pars plana vitrectomy. Several techniques for the surgical management of posteriorly dislocated IOLs have been described. If capsule support is inadequate, the dislocated IOL can be replaced with a transscleral suture-fixated IOL, an angle-supported anterior chamber IOL (AC IOL), or an iris-fixated IOL. Each procedure has advantages and disadvantages.^{3,4} The choice of each technique depends on the background of the individual case and the surgeon's experience.

In recent studies,⁵ IOL exchange with vitrectomy and a scleral suture-fixated IOL is the most frequently chosen treatment. However, complications such as retinal breaks, retinal detachment, vitreous and choroidal hemorrhage, endophthalmitis, IOL

dislocation, and iris capture have been described with this treatment. Intermittent pupillary capture of the IOL optic has been reported to occur in some series in up to 7.9% of patients.⁶ We describe a simple technique to manage this complication (**Figure 1**).

SURGICAL TECHNIQUE

Under retrobulbar anesthesia, the conjunctiva and only the nasal section of the previous 2 scleral flaps covering the transscleral sutures that fixate the IOL are dissected. If the previous scleral flap is scarred, a new partial-thickness equilateral triangular nasal scleral flap is created 2.0 mm above the previous flap. This flap is made to cover the knot of the new suture. Using a 27-gauge needle, a nasal sclerotomy is made 1.5 mm from the sclerocorneal limbus and inferior to the scleral flap, as shown in **Video 1** (available at: <http://jcrsjournal.org>). A double-armed 10-0 polypropylene suture with a straight needle on each end is inserted through the temporal sclera into the posterior chamber behind the iris plane, but in front of the IOL optic. The 10-0 polypropylene suture is then externalized by feeding it into the lumen of the 27-gauge hypodermic needle, which is removed from the eye (**Figure 2**). Using a second 27-gauge needle, the same maneuver is performed with the second needle on the other end of the suture, but in this case through the scleral flap. The 27-gauge needle is retracted, and the straight needle with the 10-0 polypropylene suture is grasped and pulled through the sclera out of the eye and fixed externally (**Figure 3**). The sutures are looped out of the eye and tied firmly under the nasal scleral

Submitted: March 30, 2014.

Final revision submitted: July 27, 2014.

Accepted: July 28, 2014.

From the Institut Catala de Retina, Barcelona, Spain.

Corresponding author: Ignasi Jürgens, PhD, Ganduxer, 117, 08022 Barcelona, Spain. E-mail: jurgens@comb.cat.

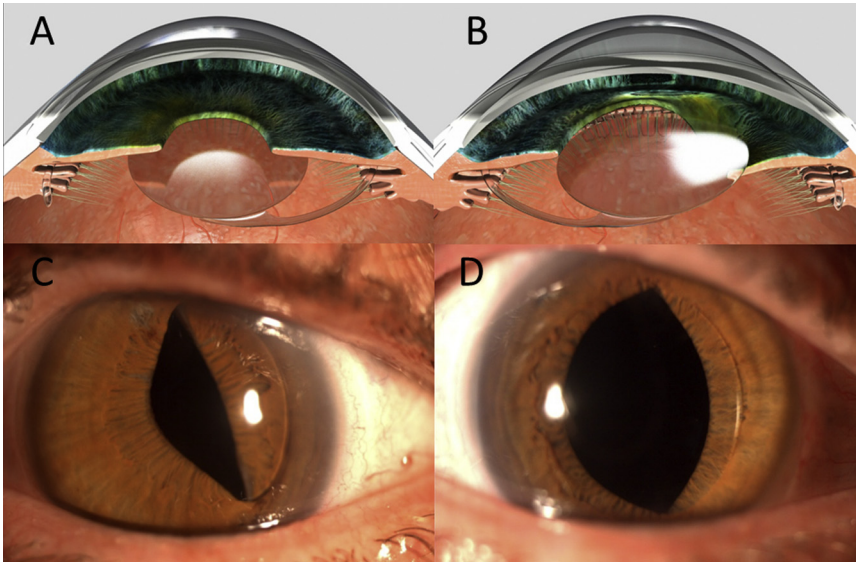


Figure 1. A: Correct position of a scleral-fixated sutured PC IOL. B: Pupillary capture of a scleral-fixated sutured PC IOL. C: Nasal pupillary block after scleral-fixated sutured PC IOL implantation, without and with (D) pupil dilation.

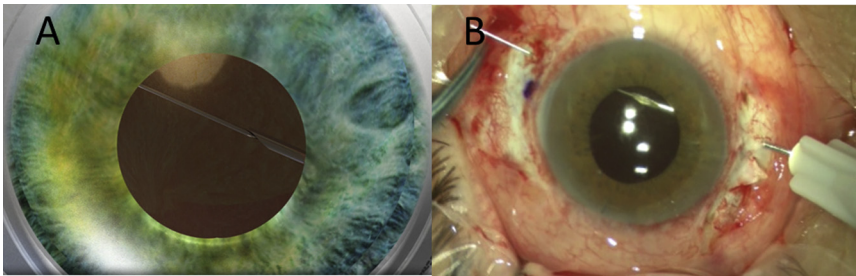


Figure 2. Insertion of the first needle with the 10-0 polypropylene suture. The 10-0 polypropylene suture is externalized by feeding the needle into the lumen of the 27-gauge hypodermic needle. Note that the suture passes behind the iris but in front of the IOL optic (A = model eye; B = patient eye).

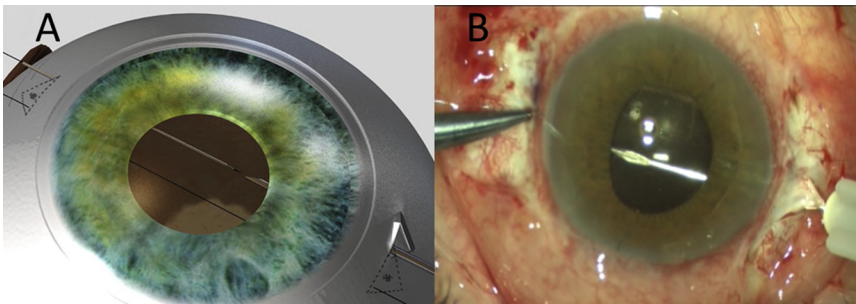


Figure 3. Insertion of the second needle through the bed of the new scleral flap. This flap will cover the knot of the suture (A = model eye; B = patient eye).




Figure 4. The knot of the 10-0 polypropylene suture is covered by the nasal scleral flap.

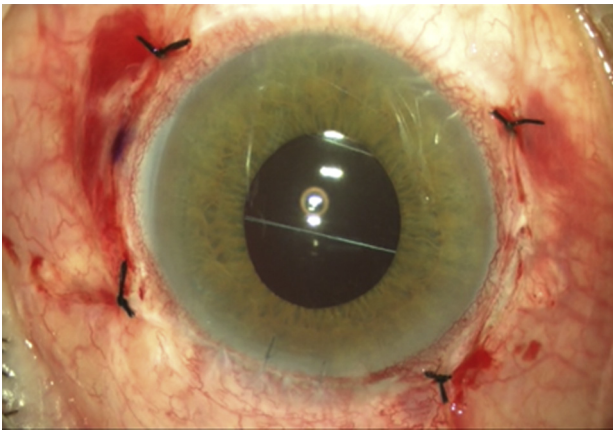


Figure 5. The scleral nasal flap is repositioned over the polypropylene knot and the conjunctival peritomy is closed.

flap after the loop (Figure 4) is tightened. The nasal scleral flap is then repositioned over the knot and the area covered by the conjunctiva (Figure 5).

The sutures prevent pupillary capture of the scleral-fixed sutured posterior chamber IOL (PC IOL) by gliding the iris over the sutures and the IOL optic and limiting the movement of the tilting IOL (Figure 6).

RESULTS

A review was conducted of 38 eyes of 33 patients with IOL dislocation who required pars plana vitrectomy and scleral-fixed sutured PC IOL implantation; the mean follow-up in these eyes was 26.79 months (range 6 to 84 months). Pupillary capture occurred in 2 eyes of 1 patient (5.3%) 1 day and 2 months after vitrectomy. Pilocarpine was not effective; the patient had bilateral

blurred vision and complained about his cosmetic problem. Our technique was performed 4 months and 8 months after the diagnosis of pupillary capture with excellent results. The follow-up has been 5 months and 6 months with no sign of recapture.

DISCUSSION

Scleral-fixed sutured PC IOLs are more frequently used to correct aphakia than AC IOLs. The position behind the iris reduces the risk for corneal endothelial damage and has the optical benefit of proximity to the ocular rotational axis and the nodal point. This technique provides IOL stability with less tendency toward tilting, decentration, and pseudophacodonesis than the use of iris-fixed IOLs. However, pupillary capture may occur in some cases.⁷

Intraocular lens iris capture is usually a transient complication. Patients may be symptomatic with blurred vision or pain, but usually the capture is merely a cosmetic problem. However, it may cause other complications such as pupillary block with secondary glaucoma and iritis and limit pupil dilation.⁸ Pupillary capture can be treated and prevented using miotic agents (pilocarpine or brimonidine), which have a relative low success rate, or laser iridotomy in cases of pupillary block, which is not always a permanently successful procedure.

There are few studies on how to treat pupillary capture in eyes with scleral-fixed sutured PC IOLs. Some authors have suggested that a reverse pupillary block may cause pupillary IOL capture.⁹ Khng et al.¹⁰ report a case series of 2 previously vitrectomized eyes with a well-positioned sutured IOL that developed

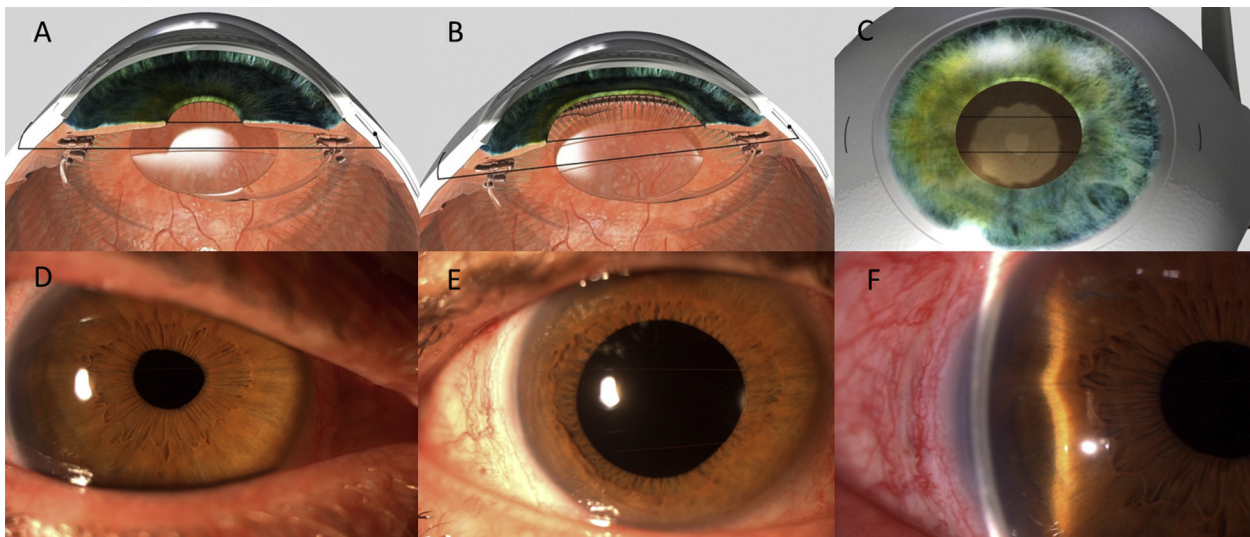


Figure 6. Correct IOL position after surgery. There is no evidence of nasal pupillary capture without dilation (A and D) and with dilation (B and E). The iris glides over the sutures, which prevent pupillary capture of the scleral-fixed sutured PC IOL (C and F).

intermittent pupillary capture as a result of a presumed reverse pupillary block. They recommend performing a neodymium:YAG peripheral iridotomy to prevent or reduce the risk for recapture when a miotic agent is poorly tolerated. Higashide et al.¹¹ also suggest that laser iridotomy may reduce the pressure gradient between the posterior and anterior chambers due to reverse pupillary block. However, in their series, 2 of the 4 eyes treated had recurrences after laser iridotomy. In some cases, surgical repositioning of the IOL optic and even IOL exchange were required despite the laser iridotomy.⁸ With the surgical technique we describe, the 2 paracentral sutures localized anterior to the IOL and posterior to the iris stabilize the IOL and guide the iris movement over the IOL optic, a less traumatic surgery than resuturing or exchanging the IOL.

In conclusion, we report a new and easy technique to treat persistent pupillary IOL capture for patients who do not respond to miotic agents or peripheral iridotomy, which results in normal pupillary function.

WHAT WAS KNOWN

- Pupillary capture of the IOL is an early complication of transscleral suture-fixated IOLs.
- Recurrence might be prevented with miotic agents, which has a relatively low success rate, or laser iridotomy, which is not always successful.

WHAT THIS PAPER ADDS

- A new, simple surgical technique for treating pupillary capture after previously scleral-fixated PC IOL resulted in normal pupil function without recurrence of the complication.

REFERENCES

1. Schneiderman TE, Johnson MW, Smiddy WE, Flynn HW Jr, Bennett SR, Cantrill HL. Surgical management of posteriorly dislocated silicone plate haptic intraocular lenses. *Am J Ophthalmol* 1997; 123:629–635
2. Oner FH, Kocak N, Saatci AO. Dislocation of capsular bag with intraocular lens and capsular tension ring. *J Cataract Refract Surg* 2006; 32:1756–1758
3. Waggoner MD, Cox TA, Ariyasu RG, Jacobs DS, Karp CL. Intraocular lens implantation in the absence of capsular support; a report by the American Academy of Ophthalmology (Ophthalmic Technology Assessment). *Ophthalmology* 2003; 110:840–859
4. Gross JG, Kokame GT, Weinberg DV; for the Dislocated In-The-Bag Intraocular Lens Study Group. In-the-bag intraocular lens dislocation. *Am J Ophthalmol* 2004; 137:630–635
5. Fernández-Buenaga R, Alio JL, Pérez-Ardoy AL, Larrosa-Quesada A, Pinilla-Cortés L, Barraquer R, Alio JL II, Muñoz-Negrete FJ. Late in-the-bag intraocular lens dislocation requiring explantation: risk factors and outcomes. *Eye* 2013; 27:795–801. Available at: <http://www.nature.com/eye/journal/v27/n7/pdf/eye201395a.pdf>. Accessed September 23, 2014
6. Bading G, Hillenkamp J, Sachs HG, Gabel VP, Framme C. Long-term safety and functional outcome of combined pars plana vitrectomy and scleral-fixated sutured posterior chamber lens implantation. *Am J Ophthalmol* 2007; 144:371–377
7. Arkin MS, Steinert RF. Sutured posterior chamber intraocular lenses. *Int Ophthalmol Clin* 1994; 34(3):67–85
8. Nagamoto S, Kohzuka T, Nagamoto T. Pupillary block after pupillary capture of an AcrySof intraocular lens. *J Cataract Refract Surg* 1998; 24:1271–1274
9. Campbell DG, Schertzer RM. Pathophysiology of pigment dispersion syndrome and pigmentary glaucoma. *Curr Opin Ophthalmol* 1995; 6(2):96–101
10. Khng C, Snyder ME, Osher RH, Cionni RJ. Cataract surgical problem. In: Masket S, ed, Consultation section. *J Cataract Refract Surg* 2005; 31:264
11. Higashide T, Shimizu F, Nishimura A, Sugiyama K. Anterior segment optical coherence tomography findings of reverse pupillary block after scleral-fixated sutured posterior chamber intraocular lens implantation. *J Cataract Refract Surg* 2009; 35:1540–1547

Video 1. A simple technique to treat pupillary capture after transscleral fixation of an intraocular lens is demonstrated.